



SAFETY PROFILE, HPLC ANALYSIS, AND EFFECT OF *VERNONIA AMYGDALINA* DELILE (ASTERACEAE) LEAVES ON STEROIDAL HORMONES ASSOCIATED WITH UTERINE FIBROID

*Imade, R. O. and Eniafe, A. E

Department of Pharmacognosy, Faculty of Pharmacy, University of Benin, PMB 1154, Benin City,
300001, Nigeria

*Author for correspondence: rose.jesuorobo@uniben.edu.ng; +2347032444024

ABSTRACT

Uterine fibroids are non-cancerous growths in the uterus that commonly develop during the reproductive years in women. The role of estrogen and progesterone in fibroid development has been well established, prompting research into potential herbal interventions to regulate these steroidal hormones. This study aimed to evaluate the safety profile and effects of ethanol extract of *Vernonia amygdalina* Delile (Asteraceae) leaves on serum estradiol and progesterone levels in female Wistar rats, as well as identify the bioactive compounds present in the extract. The leaves of *V. amygdalina* were extracted with ethanol using a Soxhlet apparatus. Wistar rats were administered the plant extract in graded doses (100 and 200 mg/kg) for 28 days after which blood samples and organs were collected for toxicity studies and hormonal assay. Additionally, High-Performance Liquid Chromatography (HPLC) was employed to identify bioactive compounds in the extract. The extract did not adversely alter any of the tested safety biochemical and hematological parameters. It boosted the immune system, induced bronchiolar dilation and improved blood flow within the vessels of the heart. The hormonal assay revealed that the extract at 100 and 200 mg/kg did not decrease serum estradiol levels. However, a significant lowering of serum progesterone was observed ($p < 0.05$). HPLC analysis identified several bioactive compounds including benzophenone, garcinoic acid, vernodaline, luteolin, and andrographoside. These findings suggest that *V. amygdalina* is safe, and possesses significant potential in reducing progesterone levels, possibly due to its diverse bioactive constituents, which may contribute to its hormone-modulatory activity.

Keywords: Estradiol, Fibroid, HPLC, Progesterone, Safety profile, *Vernonia amygdalina*

INTRODUCTION

Fibroids are the most prevalent pelvic tumors in women of reproductive age, affecting over 70% of women globally, particularly women of color (Yang *et al.*, 2021). Uterine fibroids, also known as leiomyomas, are non-cancerous tumors that develop from a single type of uterine smooth muscle cell. They can grow within the uterine wall, inside the uterine cavity, or on the outer surface of the uterus, leading to

their classification as intramural, submucosal, or subserosal fibroids (Uimari *et al.*, 2021). Their size varies widely, ranging from as small as a pea to as large as a watermelon (Uimari *et al.*, 2021). Although the precise cause of uterine leiomyoma formation remains unclear, epidemiological studies have made available substantial proof that estrogen and progesterone stimulate the growth of the

tumor, possibly as a result of continuous menstrual cycles, since it is uncommon for fibroids to occur before menarche and tend to regress following menopause (Navarro, 2021). Several epidemiological factors add to uterine fibroid risk, including age, race, early onset of menstruation, having few or no pregnancies, genetic predisposition, excess body weight, dietary habits, smoking, contraceptive use, hormone replacement therapy and exposure to elevated levels of estrogen and progesterone in the environment (Morhason-Bello and Adebamowo, 2022).

Women with uterine fibroids usually experience no symptoms, thus they often receive little medical attention, and the tumors frequently go unnoticed (Uimari *et al.*, 2021). Those with symptoms commonly report unusually heavy menstrual bleeding or painful periods, a feeling of pelvic pressure, an enlarged lower abdomen, frequent urination, discomfort during intercourse, lower back pain, pregnancy and labor complications, and reproductive challenges such as infertility (Yang *et al.*, 2022). The severity of these symptoms generally depends on the size and location of the fibroids (Yang *et al.*, 2022).

There are very limited options for treatment and prevention, with doctors often recommending myomectomy or hysterectomy (Ezejiofor and Okoroafor, 2022). Medication-based treatments, such as hormone replacement therapy, provide benefits for only six to twelve months, as long-term use can lead to significant adverse effects (Ezejiofor and Okoroafor, 2022). While uterine artery embolization and high-intensity focused ultrasound ablation are effective options, the potential risks and high costs may deter patients from choosing these treatments (Arip *et al.*, 2022). Orthodox medications are not only costly but also tend to offer only temporary relief,

highlighting the need for alternative treatment options (Koyejo *et al.*, 2021).

The limitations of conventional medicine, along with the availability, cost-effectiveness, and cultural importance of herbal remedies has led to a renewed interest in these natural alternatives (Arip *et al.*, 2022). Phytochemicals exert anti-fibroid effects by modulating hormonal pathways, particularly through the regulation of estradiol and progesterone levels (Koyejo *et al.*, 2021). Several studies have shown that plants used ethnomedicinally to treat fibroids lower the levels of these hormones which are key players in the formation of fibrotic tissues. Significantly ($P < 0.05$) elevated levels of serum estradiol and progesterone induced in rats was reportedly reduced by administration of the extract of *Scutellaria barbata* D. Don, *Curcuma longa* as well as compounds like resveratrol, curcumin, and anthocyanins, which have been found to prevent or treat fibroid through mechanisms which involve estradiol and progesterone levels (Koyejo *et al.*, 2021). Extracts of *Spondias mombin* and *Aspilia africana* have also been reported to reduce monosodium glutamate induced fibroids in rats (Eze-Steven *et al.*, 2019).

Vernonia amygdalina Delile (Asteraceae) is a plant primarily grown and utilized in traditional medicine across tropical regions of Africa and Asia (Asante *et al.*, 2024). Extracts from the plant have been reported to help suppress cancer, tumors, reduce diet-induced obesity, and treat conditions such as typhoid, inflammatory diseases, malaria, kidney disorders, and gastrointestinal issues (Ugbogu *et al.*, 2021; Asante *et al.*, 2024). Given the traditional use of the leaves of this plant by herbal practitioners in the management of uterine fibroids, it is imperative to evaluate its potential to modulate hormone levels implicated in fibroid pathogenesis. Such hormonal

modulation is a critical step in determining the plants possible antifibroid activity. Furthermore, considering that fibroid is a chronic condition, it is essential to investigate the safety profile of the plant following prolonged and repeated administration.

This study thus aimed to assess the safety of *Vernonia amygdalina* leaves, examine its subacute impact on fibroid-related steroidal hormones, and characterize its major phenolic compounds via High-Performance Liquid Chromatography (HPLC).

MATERIALS AND METHODS

Chemicals and reagents

Absolute ethanol (99.5%), distilled water, chloroform, Estradiol AccuBind Enzyme Linked Immunosorbent Assay (ELISA) kit, Progesterone AccuBind ELISA kit, Picric acid, Acacia gum. All reagents utilized in this study were of analytical grade and sourced from reputable local suppliers.

Plant material, collection and preparation

Vernonia amygdalina leaves were collected from within University of Benin premises, Benin City, Nigeria, on 30th August, 2024. The plant was identified and authenticated by a plant taxonomist, Professor Akinnibosun Henry. A voucher specimen was deposited at the Herbarium of the Department of Plant biology and biotechnology, Faculty of Life Science, with number UBH-V342. The leaves were dried at room temperature and then pulverized using a milling machine. The pulverized powder was exhaustively extracted with 99.5% absolute ethanol, using Soxhlet extraction method. The extract was reduced to dryness with a water bath at 60°C, weighed and stored in the fridge until required.

Animal handling conditions

Fifteen (15) non-pregnant Wistar rats weighing between 100 – 200g were obtained from the animal house of the Department of Pharmacology and Toxicology, Faculty of Pharmacy, University of Benin, Benin City, Nigeria, and acclimatized there. The animals were placed in separate plastic cages and allowed unrestricted access to dry grower rodent pellet (Chikun feed)® and water. They were grouped into three groups (A, B and C) having five rats each. Proper ventilation was ensured and wood shavings provided as bedding material to collect urine and faeces. The methods used for handling animals complied with the National Institute of Health Guidelines for the Care and Use of Laboratory animals. All procedures for using experimental animals were approved by the Research Ethics Committee of the Faculty of Pharmacy, University of Benin EC/FP/025/08.

Dosing of experimental animals

Group A was the control given 0.5 mL distilled water. Doses of 100 and 200 mg/kg of *V. amygdalina* extract were administered to groups B and C. They were chosen based on the plant's LD₅₀, which has previously been reported to be greater than 5000 mg/kg (Yunusa *et al.*, 2024). The rats were given daily doses for thirty days via orogastric tube. Body weights of the rats were taken on day 0, 7, 14, 21 and 28 and the dose administered was based on their recorded body weight each week.

Biochemical assays

On the 28th day, the animals were euthanized in a chloroform-saturated chamber, and blood samples collected via cardiac puncture. The blood was transferred into both plain and EDTA bottles for subacute toxicity, plasma progesterone level and plasma estradiol level analysis. Organs excised for histological examination were the kidney, liver, heart, spleen, lungs and uterus. Blood samples collected into plain

tubes were allowed to sit at room temperature for 45 minutes before being centrifuged at 3400 rpm for 10 minutes and serum stored at -25°C (Ezejiofor and Okoroafor, 2022).

Sub-acute toxicity test

The collected serum, stored at -25°C , was used for the evaluation of lipid profiles, renal function, and liver function parameters. These parameters were assessed with an automated chemistry analyzer (Selectra Pro S, Germany). Electrolyte assay was by ion selective electrode (SFRI 4000, France). The parameters assayed include creatinine (Cr), urea (Ur), aspartate aminotransferase (AST), alanine aminotransferase (ALT), alkaline phosphatase (ALP), total bilirubin (Tb), conjugated bilirubin, triglycerides (TG), total cholesterol (T-CH), low-density lipoproteins (LDL), high-density lipoprotein (HDL) and serum electrolytes (Na^+ , K^+ , Cl^- , HCO_3^-) (Ogunro and Yakubu, 2021).

Hematological analysis

Blood samples collected into EDTA-containing tubes were analysed for hematological parameters with an automated hematology analyzer (Dymind 2000, China). The parameters analysed were white blood cells (WBC), red blood cells (RBC), red blood cell distribution width (CV), hemoglobin (Hb), mean corpuscular volume (MCV), mean corpuscular hemoglobin (MCH), mean corpuscular hemoglobin concentration (MCHC), granulocytes (GRAN), platelets count (PCT) and hematocrit (HCT) (Ezejiofor and Okoroafor, 2022).

Histopathological analysis of organs

For histological analysis, the liver, heart, kidney, spleen, lungs and uterus from the sacrificed animals were fixed in 10% neutral buffered formalin solution. These tissues were subsequently dehydrated in ascending

grades of alcohol (70%, 90%, 96% and 100%), cleared in xylene, impregnated with molten paraffin wax and sectioned to slides. These sections (4–5 μm thick) were stained with hematoxylin after dewaxing with xylene and hydrating in descending grades of alcohol (100%, 96%, 70%) and water. Differentiation was done in 1% acid alcohol and the sections counter stained with eosin. Dehydration in ascending grades of alcohol was carried out again, and the sections cleared in xylene and mounted with dibutyl phthalate polystyrene using cover slips prior to microscopic examination (Eze-Steven *et al.*, 2019).

Assay of serum estradiol and progesterone levels

This was carried out using a Microplate Reader (Mindray MR-96A). E_2 AccuBind ELISA Kit was used for serum estradiol analysis while Progesterone ELISA Kit was used for serum progesterone analysis. The instructions in the manufacturers' manuals were followed. The absorbance was read at 450 nm within 15 min of adding the stop solutions. The concentration of estradiol and progesterone in the samples were extrapolated from dose response curves (Lin *et al.*, 2020).

HPLC procedure

The HPLC analysis was conducted at Bato Chemical Laboratory in Lagos, Nigeria, using a Shimadzu Nexera MX system. The chromatography was performed on a uBondapak C_{18} reverse-phase column with dimensions of 100 mm in length, 4.6 mm internal diameter, and 7 μm thickness. The mobile phase consisted of acetonitrile and water, with a flow rate of 0.08 mL/min for water and 5 mL/min for acetonitrile. The HPLC system was equipped with a UV-Vis diode array detector set at 254 nm within the UV-visible spectrum. The pump pressure used was 15 MPa. Initially, standard analyte profiles were injected into the HPLC,

producing a chromatogram with specific peak areas and profiles. These data were used to define a reference window in the HPLC for the test sample analysis. Next, aliquots of the extracted test sample were injected into the equipment to generate a corresponding chromatogram with its own peak area and profile. The peak area of the sample was then compared to that of the standard, and the standard's concentration was used to determine the sample's concentration (Zakaria *et al.*, 2020).

Data analysis

Bar graphs were generated with GraphPad Prism for Windows (version 7), and the data analysed with one-way analysis of variance (ANOVA) followed by Tukey–Kramer multiple comparison test. A p-value of \leq

0.05 was considered statistically significant in all analyses.

RESULTS

Sub-acute toxicity results

Effect of *Vernonia amygdalina* leaves extract on food consumption and body weight

Repeated dosing over a 28-day period did not result in mortality or any outward display of toxicity in the test animals. Normal eating habits were observed and a gradual increase in weight was seen in all test groups (Table I), though at 100 mg/kg there was significant reduction in weight on day 21 ($P \leq 0.01$) and 28 ($P \leq 0.05$) compared to the normal group.

Table I: Change In Mean Body Weights of the Rats at Different Days of The Experiments

Dose (mg/kg)	Days of Observation				
	0	7	14	21	28
Control	111±3.54	13±8.65	27.8±3.28	41.6±7.97	46±6.95
100	163±4.41	20.6±4.61	22.4±4.18	16.6±4.26 ^b	25.4±4.63 ^a
200	145.6±5.02	22.2±6.59	3.4±6.77 ^a	145.6±5.02	33.2±9.05

Data are expressed as mean \pm SEM, n=5, ^a = $P \leq 0.05$, ^b = $P \leq 0.01$ compared to control, with Tukey-Kramer multiple comparison test

Effect of *Vernonia amygdalina* leaves extract on serum biochemical parameters

Effect on lipid profile tests

All the lipid profile test parameters obtained from the serum of the control and test groups at different doses were not significantly different ($p > 0.05$) (Table II).

Effect on kidney function test parameters

Effect of *Vernonia amygdalina* leaves extract on hematological parameters

The results of the hematological parameters revealed no significant effect ($p > 0.05$) on

Extract administration at all doses did not significantly alter the concentration of sodium, potassium, chloride, urea and creatinine ($P > 0.05$) (Table III)

Effect on liver function test parameters

The liver function test parameters were also not significantly altered by administration of the extract (Table IV).

all hematological parameters tested as they were all within normal range (Table V).

Table II: Lipid Profile Parameters After 28 Days of Administration

Parameters	Dose (mg/kg)		
	Control	100	200
T-CH (mg/dL)	82.20 ± 4.03	88.00 ± 5.54	91.60 ± 3.64
HDL (mg/dL)	25.40 ± 0.98	27.20 ± 1.28	27.60 ± 0.98
LDL (mg/dL)	36.60 ± 2.94	40.40 ± 4.29	44.60 ± 3.37
TG (mg/dL)	100.60 ± 2.89	101.4 ± 2.32	95.60 ± 2.44

Data are expressed as mean ± SEM, n=5. There was no significant difference in the values of the test groups compared to the control. Total cholesterol (T-CH), high-density lipoprotein (HDL), low density lipoprotein (LDL), triglyceride (TG).

Table III: Kidney Function Test Parameters After 28 Days Of Administration

Parameters	Dose (mg/kg)		
	Control	100	200
Urea (mg/dL)	45.40 ± 2.25	37.20 ± 3.31	44.80 ± 3.22
Creatinine (mg/dL)	0.68 ± 0.06	0.72 ± 0.04	0.80 ± 0.09
Na ⁺ (mmol/L)	140.60 ± 1.47	139.20 ± 1.32	140.40 ± 1.50
K ⁺ (mmol/L)	4.12 ± 0.10	4.34 ± 0.18	4.18 ± 0.14
HCO ₃ ⁻ (mmol/L)	21.40 ± 0.28	21.20 ± 0.73	21.40 ± 1.08
Cl ⁻ (mg/dL)	104.80 ± 0.73	104.8 ± 1.32	105.80 ± 0.80

Data are expressed as mean ± SEM, n=5. There was no significant difference in the values of the test groups compared to the control.

Table IV: Liver Function Test Parameters After 28 Days Of Administration.

Parameters	Dose (mg/kg)		
	Control	100	200
AST (µ/L)	77.40 ± 4.27	62.40 ± 4.20	71.60 ± 2.77
ALT (µ/L)	45.80 ± 2.42	37.00 ± 2.43	42.20 ± 1.66
ALP (µ/L)	59.60 ± 3.54	54.00 ± 5.41	59.80 ± 1.53
Tb (mg/dL)	0.28 ± 0.02	0.28 ± 0.02	0.28 ± 0.02
Cb (mg/dL)	0.10 ± 0.00	0.10 ± 0.00	0.10 ± 0.00
Tp (g/dL)	6.34 ± 0.12	6.40 ± 0.25	6.50 ± 0.36
ALB (g/dL)	2.82 ± 0.02	2.98 ± 0.05	2.88 ± 0.06
GLo (g/dL)	3.52 ± 0.14	3.42 ± 0.25	3.62 ± 0.36

Data are expressed as mean ± SEM, n=5. There was no significant difference in the values of the test groups compared to the control. Alkaline phosphatase (ALP), alanine aminotransferase (ALT) Aspartate aminotransferase (AST), total bilirubin (Tb), conjugated bilirubin (Cb), total protein (Tp), albumin (ALB), globulin (GLo).

Histopathology Result

Plate A shows normal heart architecture with well-defined bundles of cardiomyocytes (CM), interstitial space (IS),

coronary artery (CA) and cardiac veins. Sections of the heart taken from rats treated with the plant extract also showed normal architecture as well as active vascular congestion and vasodilatation (DC). In the

control group, the liver showed normal architecture (Plate B), with well-defined hepatocytes (HC), sinusoids (SI) and portal triad (hepatic portal vein (PV), artery (HA) and bile duct (BD)). The 100 mg/kg extract group exhibited similar histology. In

contrast, the 200 mg/kg group demonstrated Kupffer cell activation (KA), periportal inflammatory cell infiltration (PI), hepatocytes with conspicuous nucleoli (HN), and signs of portal hepatitis (PH).

Table V: Results of Hematological Assay After 28 Days Administration Of *Vernonia Amygdalina*

Parameters	Dose (mg/kg)		
	Control	100	200
WBC ($10^3/\mu\text{L}$)	14.64 ± 1.50	12.54 ± 1.59	21.04 ± 2.31
LYM (%)	83.00 ± 1.66	23.26 ± 1.23	81.22 ± 3.03
MON (%)	2.06 ± 0.33	1.68 ± 0.29	2.66 ± 0.25
NEU (%)	10.56 ± 1.65	11.14 ± 0.73	11.76 ± 2.14
EOS (%)	0.84 ± 0.37	0.54 ± 0.17	0.56 ± 0.15
BAS (%)	3.50 ± 0.42	3.38 ± 0.73	3.80 ± 0.87
RBC ($10^6/\mu\text{L}$)	6.38 ± 0.24	6.33 ± 0.21	6.63 ± 0.13
HGB (g/dL)	13.50 ± 0.51	13.68 ± 0.58	14.26 ± 0.27
HCT (%)	40.20 ± 1.56	40.80 ± 1.66	42.20 ± 0.86
MCV (μm^3)	50.28 ± 0.42	51.12 ± 1.05	51.44 ± 0.88
MCH (pg)	21.16 ± 0.10	21.60 ± 0.43	21.52 ± 0.33
MCHC (g/dL)	42.12 ± 0.37	42.26 ± 0.15	41.80 ± 0.13
RDWC (%)	16.28 ± 0.88	14.88 ± 0.29	15.56 ± 0.39
RDWS (μm^3)	26.96 ± 1.65	24.78 ± 0.67	25.08 ± 0.81
PLT ($10^3/\mu\text{L}$)	741.20 ± 98.38	707.80 ± 49.26	592.40 ± 21.90
MPV (μm^3)	6.54 ± 0.27	6.36 ± 0.09	6.36 ± 0.09
PCT (%)	0.49 ± 0.08	0.45 ± 0.03	0.45 ± 0.03
PDW (%)	24.98 ± 1.43	22.02 ± 1.78	22.02 ± 1.78
P-LCR (%)	5.96 ± 2.29	4.20 ± 0.45	4.20 ± 0.45

Data are expressed as mean ± SEM, n = 5. . There was no significant difference in the values of the test groups compared to the control. White blood cell (WBC), lymphocytes (LYM), monocyte (MON), neutrophil (NEU), eosinophil (EOS), basophil (BAS), red blood cells (RBC), hemoglobin (HGB), hematocrit (HCT), mean corpuscular volume (MCV), mean corpuscular hemoglobin (MCH), mean corpuscular hemoglobin concentration (MCHC), red blood cell distribution width SD (RDW-SD), red blood cell distribution width-coefficient of variation (RDW-CV), platelet (PLT), mean platelet volume (MPV), platelet distribution width (PDW), platelets count (PCT), platelet larger cell ratio (P-LCR).

For the kidney, the control and treated groups revealed normal histological architecture (Plate C), with well-defined tubules (TU), glomeruli (GL), interstitial space (IS) and arcuate blood vessels.

Plate D showed normal spleen architecture with well-defined white pulp (WP), sinuses (SI), splenic arterioles (SA), and red pulp (RP). Sections taken from rats treated with 100mg/kg body weight of *V. amygdalina*,

revealed increased red cell sequestration (RS) and follicular activation (FA).

Lungs from the control group in Plate E revealed well-defined alveolar sacs (AL), interstitial space (IS), bronchioles (TB), bronchial blood vessels (BA) and active vascular congestion (AC). Sections from rats given the extract revealed normal alveolar

sacs and added beneficial changes of bronchiolar dilation (BD). The uterus taken from the control and treated groups (Plate F) revealed normal histological architecture with well-defined uterine cavity, surrounded by the endometrial membrane (EM) and endometrium containing the glands (EG) embedded in the stroma ES).

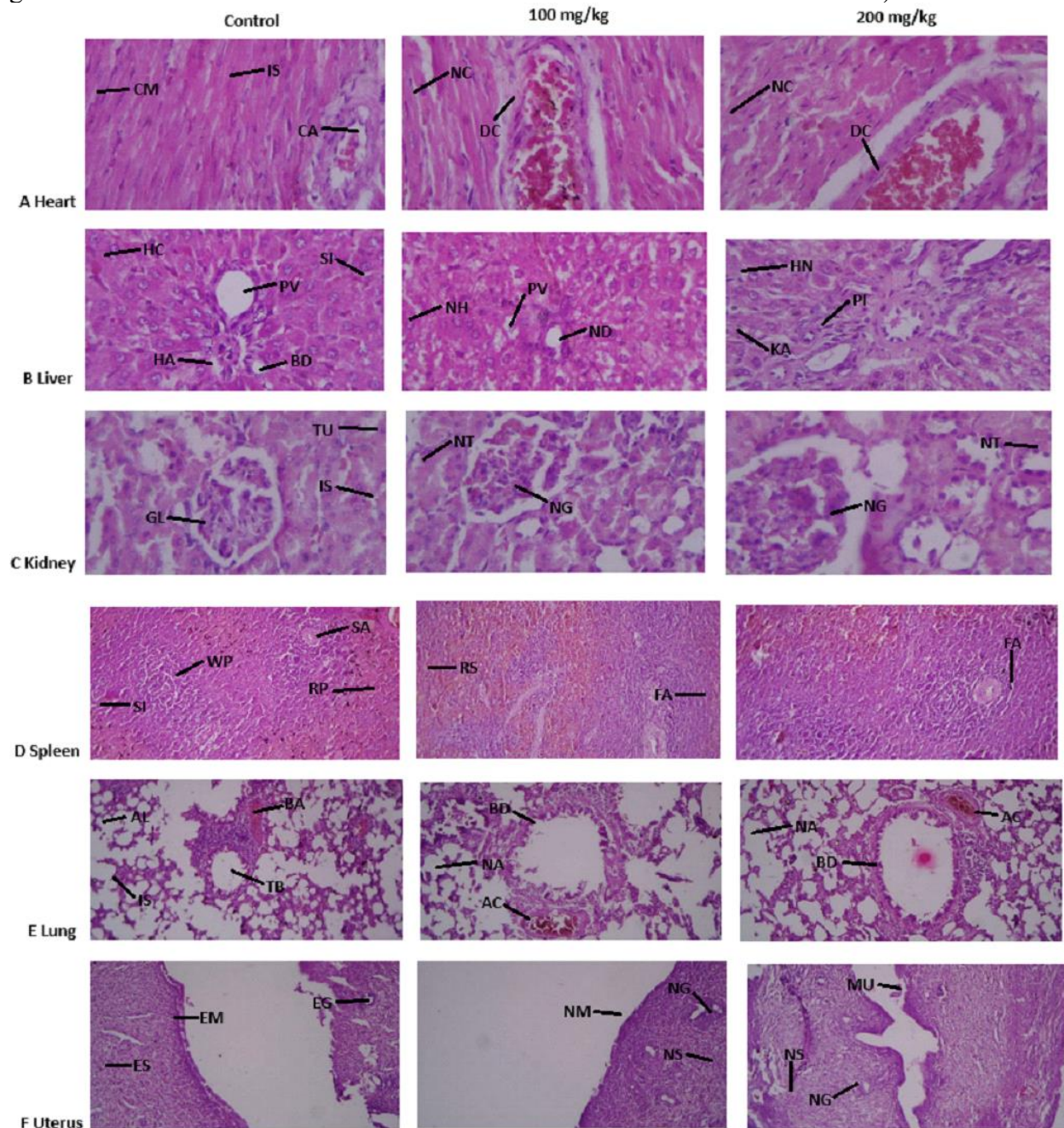


Figure 1: H&E 400 X Wistar Rat organ sections

Effect on steroidal hormones

There was no significant change in estradiol levels in rats administered 100 and 200 mg/kg *V. amygdalina* extract (Figure 1) in comparison with the control ($p>0.05$).

Treatment with 100 and 200 mg/kg of the extract resulted in 57.50% and 61.52% (Figure 2) decrease respectively in progesterone levels ($p\leq 0.05$).

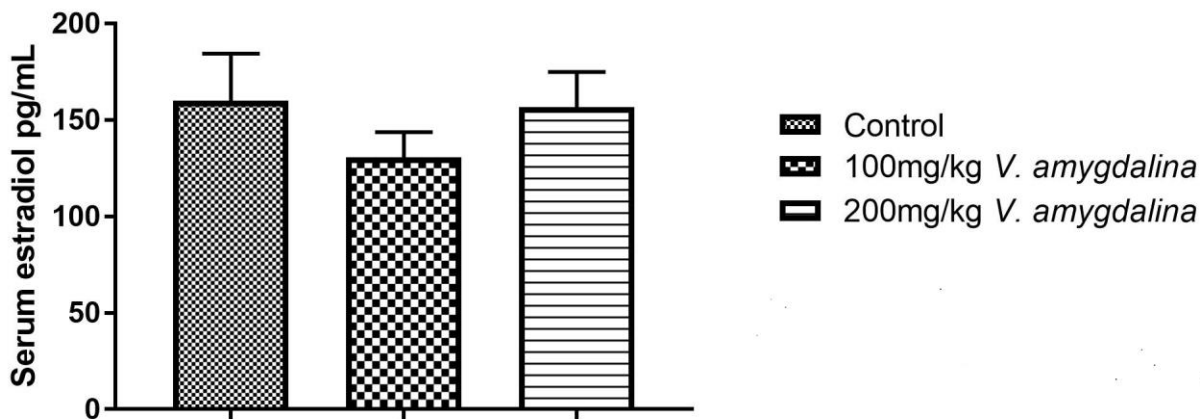


Figure 1: Effect of the ethanol extract of *V. amygdalina* leaves on total estradiol content in female Wistar rats.

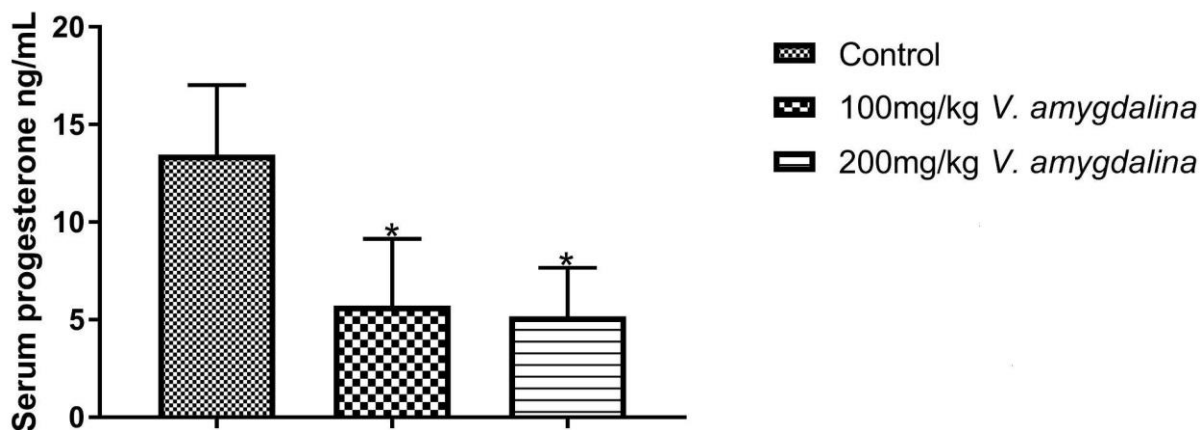


Figure 2: Effect of the ethanol extract of *V. amygdalina* leaves on total progesterone level in female Wistar rats. According to Tukey-Kramer multiple comparison test, there was a significant difference between the test groups and the control group $*P\leq 0.05$.

HPLC analysis result

HPLC analysis of ethanol extract of *V. amygdalina* leaves identified benzophenone, garcinoic acid, vernodalol, vernonioside A, vernonioside B, and vernomygdin as the predominant compounds. Additionally,

smaller quantities of vernodalol, luteolin, myrtenal, garanal, ascaridiol, myrtenol, myrenol, and andrographoside were detected (Table VI). The HPLC chromatogram illustrating the peaks corresponding to these compounds is shown in Figure 3.

Table VI: HPLC analysis result of ethanol extract of *V. amygdalina* leaves

Components	Retention time (mins)	Area	Height	Concentration (mg/g)
Benzophenone	1.300	215.3160	15.855	0.15
Garcinoic Acid	1.850	99.2715	12.194	0.07
Vernodalol	2.183	84.237	9.260	0.06
Vernodalol	3.050	7.8990	4.999	0.01
Vernonioside A	4.000	113.2030	3.516	0.08
Vernonioside B	5.316	88.1380	4.129	0.06
Vernomygdin	6.200	289.9805	13.873	0.20
Luteolin	8.166	39.9670	1.939	0.03
Myrtenal	10.616	30.9990	2.549	0.02
Garanal	11.283	45.5040	2.423	0.03
Ascaridiol	12.750	36.1230	2.698	0.03
Myrtenol	13.433	63.9960	2.782	0.02
Myrenol	13.983	30.4350	2.251	0.02
Andrographoside	14.333	41.1630	2.994	0.03




Figure 3: High Performance Liquid Chromatography (HPLC) chromatogram of compounds in ethanol extract of *Vernonia amygdalina* leaves

DISCUSSION

Administration of the extract over a 28-day period resulted in a progressive increase in body weight among all groups from the beginning to the end of the study, indicating that the extracts were well tolerated and relatively non-toxic to the rats. Although all groups showed an increase in body weight, the weight gain in the test groups was markedly lower than that of the control group. This diminished weight gain among the treated animals could be influenced by several factors. Since the plant extracts were administered via the oral route, the unpleasant taste of the extract of *V. amygdalina*, a plant known for its characteristic bitter taste, could have impacted on the feeding habits of the animals. Extracts from the plant, particularly cold-water extracts, have been reported to reduce diet-induced obesity (Ugbogu *et al.*, 2021).

LDL, total cholesterol and triglycerides are three primary components of the lipid profile that are linked to cardiovascular disease (Zakaria *et al.*, 2020). The levels of these parameters were not significantly different ($p > 0.05$) from the control group, which is in tandem with other published studies (Rachmaini *et al.*, 2024). The primary function of the kidneys is to eliminate harmful waste products generated by normal metabolic activities and transported by the blood. Additional research amply supports the capacity of plant extracts to function as potent free radical scavengers in the kidney, preventing harmful effects from lipid peroxidation, which raises biochemical markers like creatinine and urea by rupturing membranes (Akowuah *et al.* 2015). Increased serum levels of biochemical indicators such as transaminases and alkaline phosphatase are linked to liver toxicity (Akowuah *et al.* 2015). There was no significant elevation in

these parameters ($p > 0.05$) compared to the control. *V. amygdalina* leaves has been reported to possess saponins, alkaloids, flavonoids, anthraquinones, and phenol as dominant secondary metabolites (Degu *et al.*, 2024). The plant has been reported to possess hepatoprotective as well as antioxidant activities which could be explained by the antioxidant potential of its flavonoid and phenolic constituents (Ugbogu *et al.*, 2021)

Blood indices are used to monitor the physiological and pathological state of the body (Rachmaini *et al.*, 2024). The extract did not significantly change the parameters which is consistent with other studies (Akowuah *et al.*, 2015; Rachmaini *et al.*, 2024) and so proved to be safe at the doses used.

Histopathological examinations demonstrated an increase in red blood cell sequestration within the splenic red pulp and a significant stimulation of the spleen's local immune function. The heart exhibited favorable hemodynamic and vasogenic adaptations, characterized by enhanced blood flow and vasodilation. Mild portal inflammation in the liver was the sole toxicological finding, occurring at a dose of 200 mg/kg.

The doses of *V. amygdalina* leaves used showed no significant lowering of serum estradiol levels in test animals. On the contrary, serum progesterone levels were significantly reduced.

Progesterone signaling is essential for the development and growth of fibroids, as it stimulates its cell proliferation by triggering various genetic and epigenetic signaling pathways (Ali *et al.*, 2023), The lowering of serum progesterone levels will impact on the fibroid cells as its lowering will consequently result in decrease in the expression of proliferating cell nuclear

antigen (PCNA), which will in turn lead to a fall in both the number of fibroid cells and the overall tumor size. And same goes for other signaling pathways through which progesterone plays its role in uterine fibroid growth (Koyejo *et al.*, 2021). The extracellular matrix (ECM) in fibroids is abnormal and may contribute to the growth and maintenance of the tumors (Koyejo *et al.*, 2021). Collagen is a major component of the ECM in fibroids and is essential for their growth and stability. Progesterone has been shown to increase collagen synthesis in fibroid cells (Koyejo *et al.*, 2021).

V. amygdalina induces cell cycle arrest and apoptosis in cancer cells via gene regulation (Joseph *et al.*, 2020). These pharmacological activities on cancer cells can also be relevant in treatment of uterine fibroids as one of the growth mechanisms of fibroid cells is inhibition of apoptosis by progesterone (Ali *et al.*, 2023).

From the HPLC analysis, the six most dominant constituents in ethanol extract of *V. amygdalina* leaves are benzophenone, garcinoic acid, vernodalin, vernonioside A, vernonioside B and vernomygdin. Benzophenones have demonstrated notable anti-inflammatory activities. Research suggests that some naturally occurring benzophenones can suppress the production of pro-inflammatory mediators, highlighting their potential as safer alternatives to traditional non-steroidal anti-inflammatory drugs (NSAIDs) (Jeelani *et al.*, 2024).

Naturally occurring benzophenones also possess strong antioxidant properties, which help in scavenging free radicals and protecting cells from oxidative stress. This activity is crucial for preventing cellular damage and may contribute to their therapeutic potential in various diseases (Marinov *et al.*, 2023) including fibroid. Benzophenone derivatives have shown

significant anticancer (Lei *et al.*, 2024), antimicrobial and cytotoxic properties (Marinov *et al.*, 2023).

Vernomygdin is a sesquiterpene lactone which has demonstrated notable pharmacological activities: anticancer, anti-inflammatory, antimicrobial, antioxidant and hepatoprotective activities. It has also shown promise as an anticancer agent (Farombi, 2011) (Degu *et al.*, 2024).

Vernonioside A belongs to the class of steroidal saponins. Its antioxidant, antimicrobial, anti-inflammatory, and anticancer activities alongside other pharmacological activities have been documented (Degu *et al.*, 2024).

These anti-inflammatory, antitumor, antioxidant, and cytotoxic properties of these bioactive compounds serve valid complementary roles in management of uterine fibroids. As chronic inflammation is linked to fibroid growth, pro-inflammatory cytokines promote cell proliferation and fibrosis in the uterine tissues (Ali *et al.*, 2023; Usunomena and Tinuade, 2016). Anti-inflammatory agents reduce these cytokines, inhibit COX-2 enzymes, and decrease fibrosis, potentially slowing fibroid progression (Jeelani *et al.*, 2024). While fibroids are benign, their excessive cell proliferation shares similarities with tumor growth. Anticancer compounds modulate signaling pathways like Wnt/ β -catenin and PI₃K/Akt, which are involved in fibroid growth, helping to reduce size and prevent further development (Ali *et al.*, 2023).

CONCLUSION

Vernonia amygdalina ethanol extract showed minimal toxicity and beneficial vascular effects, while significantly lowering serum progesterone in female Wistar rats, revealing its hormone-

modulatory activity and potential for further antifibroid research.

Conflict of interest

The authors have no competing interests.

Acknowledgements

We would like to thank Mrs. Queen Okoro and Mr Iyayi Teophilus Akhere of the University of Benin Teaching Hospital in Benin City for their respective assistance in the preparation of the histology slides and the serum biochemical analysis respectively. Professor Gerald Eze of Anatomy department is also greatly appreciated for his help in interpreting the histology slides.

References

Akowuah GA, May LLY, Chin JH. (2015). Toxicological evaluation of *Vernonia amygdalina* methanol leave extract in rats. *Orient Pharm Exp Med*. DOI: 10.1007/s13596-015-0194-6

Ali M, Ciebiera M, Vafaei S, Alkhrait S, Chen HY, Chiang YF, Huang KC, Feduniw S, Hsia SM, Al-Hendy A (2023). Progesterone Signaling and Uterine Fibroid Pathogenesis; Molecular Mechanisms and Potential Therapeutics. *Cells*.;12(8):1117. doi: 10.3390/cells12081117

Arip M, Yap VL, Rajagopal M, Selvaraja M, Dharmendra K, Chinnapan S (2022). Evidence-based management of uterine fibroids with botanical drugs- a review. *Front Pharmacol*. 13:878407. doi: 10.3389/fphar.2022.878407

Asante DB, Wiafe GA, Tsegah KM and Domey NK (2024). Therapeutic Benefits of *Vernonia amygdalina* in the Treatment of Inflammation and Its Associated Diseases. *Clin Complement Med Pharmacol*. 4(1) <https://doi.org/10.1016/j.ccmp.2023.100122>

Badawy A, Shady NW, Maklad SMA, Ait-Allah AS (2022). The use of green tea in the treatment of symptomatic uterine fibroids. *Int J Health Sci*. 6(S1): 3116–3135. <https://doi.org/10.53730/ijhs.v6nS1.5353>

Degu S, Meresa A, Animaw Z, Jegnie M, Asfaw A, Tegegn G (2024). *Vernonia amygdalina*: a comprehensive review of the nutritional makeup, traditional medicinal use, and pharmacology of isolated phytochemicals and compounds. *Front Nat*

Prod. 3:1347855. <https://doi.org/10.3389/fntpr.2024.1347855>

Ezejiofor TIN, Okoroafor CH (2022) Effects of ethanol extracts of *Diodia sarmentosa* leaves on biochemical and histopathological indices of monosodium glutamate-induced uterine leiomyoma in rats. *Biomed Res Ther*. 9:5140–5148. DOI: 10.15419/bmrat.v9i7.749

Eze-Stephen PE, Udedi SC, Ude CM (2019). Effects of *Spondias mombin* and *Aspilia africana* Aqueous Extracts on Rats with Monosodium Glutamate-Induced Leiomyoma. *Cross Current Int J Med Biosci*. 1(1): 26-32.

Farombi EO, Owoeye O (2011). Antioxidative and chemopreventive properties of *Vernonia amygdalina* and *Garcinia biflavonoid*. *IJERPH*. 8(6):2533-55. doi: 10.3390/ijerph8062533

Jeelani M, Fouotsa H, Mohammed OA, Alfaifi J, Adebayo S, Ahmed MM, Yahia AIO, Eissa H, Bahashwan E, Mohammed NA, Alotaibi YA, Asiri AY, Rezigallah A, Alharthi MH, Dzoyem JP, Isa AI (2024), Naturally occurring benzophenones and xanthenes from *Garcinia smeathmannii* (Planch. & Triana) Oliv. displayed anti-inflammatory effects by modulating the activities of inflammatory mediators in LPS-stimulated RAW 264.7 macrophages. *Front Pharmacol*. **A915:1370073**. doi: 10.3389/fphar.2024.137007

Joseph J, Lim V, Rahman HS, Othman HH, Samad NA (2020). Anti-cancer effects of *Vernonia amygdalina*: A systematic review. *Trop J Pharm Res*.19(8) DOI:10.4314/tjpr.v19i8.29

Koyejo OD, Rotimi OA, Abikpa EN, Hello OA, Rotimi SO (2021). “A Review of the Anti-Fibroid Potential of Medicinal Plants: Mechanisms and Targeted Signaling Pathways: *TJNPR*. 5(5): 792–804. doi.org/10.26538/tjnpr/v5i5.1

Lei C, Yang W, Lin Z, Tao Y, Ye R, Jiang Y, Chen Y, Zhou B. (2024). Synthesis and bioactivity investigation of benzophenone and its derivatives. *RSC*:14, 20339-20350

Lin Y, Yang C, Tang J, Li C, Zhang Z, Xia B, Li Y, He Q, Lin L, Liao D. (2020). Characterization and anti-uterine tumor effect of extract from *Prunella vulgaris* L. *BMC Complement Med Ther*. 20, 189. <https://doi.org/10.1186/s12906-020-02986-5>

Marinov T, Kokanova-Nedialkova Z, Nedialkov PT (2023). Naturally Occurring Simple Oxygenated

Benzophenones: Structural Diversity, Distribution, and Biological Properties. *Diversity*, 15(10), 1030; <https://doi.org/10.3390/d15101030>

Morhason-Bello IO, Adebamowo CA (2022). Epidemiology of uterine fibroid in black African women: a systematic scoping review. *BMJ Open*. 12:e052053. doi:10.1136/bmjopen-2021-052053

Navarro A, Bariani MV, Yang Q, Al-Hendy A (2021). Understanding the Impact of Uterine Fibroids on Human Endometrium Function. *Front Cell Dev Biol*. 9:633180. doi: 10.3389/fcell.2021.633180

Ogunro OB, Yakubu MT (2021). Antifertility effects of 60-day oral gavage of ethanol extract of *Spondias mombin* leaves in guinea pigs: a biochemical, reproductive and histological study. *Asian Pac J Reprod*. 10: 56–67. doi:10.4103/2305-0500.311609

Rachmaini, F., Abdillah, R., Anshari, H., Juwita, D. A. (2024). Sub-acute Toxicity Study of Bitter Leaf (*Vernonia amygdalina* Del.) Aqueous Fraction on Haematological Parameters. *TJNPR*. 8(3), 6519-6524. <https://doi.org/10.26538/tjnpr/v8i3.8>

Ugbogu EA, Okezie E, Dike ED, Agi GO, Ugbogu OC, Ibe C, Iweala EJ (2021). The Phytochemistry, Ethnobotanical, and Pharmacological Potentials of the Medicinal Plant-*Vernonia amygdalina* L. (bitter Leaf). *Clin Complement Med Pharm*. 1(1). <https://doi.org/10.1016/j.ccmp.2021.100006>

Uimari O, Nazri H, Tapmeier T (2021). Endometriosis and Uterine Fibroids (Leiomyomata): Comorbidity, Risks and Implications. *Front Reprod Health*. 3:750018. doi: 10.3389/frph.2021.750018

Usunomena U, Tinuade OO (2016). Anti -anemic, Anti-necrotic and Anti-fibrotic effect of *Vernonia amygdalina* post-treatment in Dimethylnitrosamine (DMN)-administered rats. *NIJOPHASR*. 5(2):1–7. Available at: <https://nijophasr.net/index.php/nijophasr/article/view/121>.

Yang Q, Ciebiera M, Bariani MV, Ali M, Elkafas H, Boyer TG, Al-Hendy A (2022). Comprehensive Review of Uterine Fibroids: Developmental Origin, Pathogenesis, and Treatment. *Endocr Rev*. 43(4):678-719. doi: 10.1210/endrev/bnab039

Yunusa AY, Yakasai MA, Namadina MM (2024). Evaluation of Pharmacognostic and Acute toxicity of *Vernonia amygdalina* Leaves. *DUJOPAS*. 10 (4a):70-80. <https://dx.doi.org/10.4314/dujopas.v10i4a.8>

Zakaria N, Mohd KS, Ahmed Saeed MA, Ahmed Hassan LE, Shafaei A, Al-Suede FSR, Memon AH, Ismail Z (2020). Anti-Uterine Fibroid Effect of Standardized *Labisia Pumila* Var. *Alata* Extracts *In Vitro* and in Human Uterine Fibroid Cancer Xenograft Model. *APJCP*. 21(4):943-951. doi: 10.31557/APJCP.2020.21.4.943